



Role of Agnikarma in De Quervain's disease: a practical experience.

Kamalakar V. Gajare¹, Ketan P. Garje^{*2}

1. Associate Professor,

2. M.S. Scholar,

Department Of Shalyatantra, Sumatibhai Shah Ayurveda Mahavidyalaya,

Malwadi, Hadapsar, Pune, Maharashtra

*Corresponding author: Email: ketan.garje@gmail.com

ABSTRACT:-

A case study was conducted to evaluate the conservative management of a patient presenting with left sided wrist and thumb pain diagnosed as De Quervain's tenosynovitis with *Agnikarma*. A 40-year-old female with left-sided De Quervain's tenosynovitis that began after a long periods of house hold activities like cooking, squeezing of clothes, mopping, gardening, cutting vegetables. Intervention and outcome Treatment included *Agnikarma* 3 sittings with a gap of one week. Patient was advised to rest, elevation and eccentric rehabilitation exercises. The positive outcome was a complete resolution of the patient's complaint.

Keywords:

De-Quervain's tenosynovitis, *Agnikarma*, *Snayugata Vata*

Introduction:

De Quervain's disease is called gamer's thumb or mother's thumb. It is a common pathological condition of the wrist. Although the exact mechanism of De Quervain's disease has not been determined, the cause of this disease is thought to be due to thickening of the synovial sheath containing the extensor pollicis brevis (EPB) and abductor pollicis longus (APL) tendons, which leads to irritation of the muscles, causing pain and swelling over the radial side of the wrist in patients along with an increased difficulty in gripping objects.(1) De Quervain's tendon sheaths to be thickened and fibrosed with nodularities, but no inflammatory changes being present. More commonly found in perimenopausal and pregnant women, de Quervain's disease has been linked to overuse, although no

clear evidence has supported this notion. (2, 3) This presentation is not unique to de Quervain's disease, as pain and discomfort over the radial part of the distal wrist can also be a sign of intersection syndrome, osteoarthritis of the thumb carpometacarpal joint, or Wartenberg's syndrome. A thorough history and a series of physical examination maneuvers, including the Finkelstein test, can help differentiate between these causes.

On the basis of its sign and symptoms, De Quervain's tenosynovitis can be correlated with the condition of *Snayugata Vata* (*S. Vata*) described in *Ayurveda*. *Snayugata Vata* is developed when the *vata dosha* aggravates due to *vataprakopak vihara i.e. atichesta, ativyayam*, etc.(4) and gets localized in *snayu* of *mani bandha sandhi*. A type of *vayu* i.e. *vyavay* is ultimately unable to carry out the function of *manibandha sandhi* (wrist joint) and thumb smoothly. The features such as pain, stiffness, restricted movement, etc., develop in this region. These symptoms may develop in *kaphavritta vayu*. Hence it is also considered as important causative factor for manifestation of *snayugata vata*. *Ayurveda* have *shaman and shodhan chikitsa*. Variety of medical procedure mentioned in *Ayurveda samhita* as like *ksharkarma, lepanam* etc. *Agnikarma* is one of the important procedures described in *Ayurveda*. In this fast lifestyle patients

need instant result on all pain. *Agnikarma* is one of the fast procedures to reduced *vedana* (pain). Many *samhitas* have description of *Agnikarma*. From meaning to indication, contraindication, its superiority all information included in *charak, sushrut, vagbhat, harita samhita*. *Acharya Dalhana* has given explanation regarding the shapes of *Agnikarma* in his commentary. This *Agnikarma* is original idea of modern cauterization procedure

Indications of Agnikarma:

A number of diseases and conditions have been explained by *sushruta* in text where *Agnikarma* as therapeutic measure has been indicated as below:

If there is excessive pain (Due to *vataprakopa*) in *twak* (skin), *mansa* (muscles), *sira* (veins), *snayu*, *sandhi* (joints), *asthi* (bones) ; *Grahnthi* (lymphnodes), *arsha* (piles), *bhagandara* (fistula in ano), *apachi*(lymphadenitis), *shlipad* (filreasis), *charmakil* (warts), *tilkalaka* (pigmented moles), *antravrudhi* (inguin-oscrotal hernia), excessive bleeding from *sandhi* (joints), *siracheda* (cutting of veins), *nadivvana*(sinus).(5)

Pre-operative Measures –

Before going for *Agnikarma* proper assessment should be made. Instruments required for *Agnikarma* like *pippali*, *shalaka* and *plota*, *pichu*, *grita*, *madhu*,

source of *Agni* should be kept ready. *Pichhila anna* should be given before the procedure. Patient should be empty stomach in cases like urolithiasis, in different abdominal diseases, piles, fistula, and obstructed labour.

Principal procedure of Agnikarma:

Before doing the procedure of *Agnikarma*, *swasthikvachan* should be done; the patient kept in suitable position by keeping head in the East direction and held by expert assistants to avoid movement. After this the surgeon should make the different shapes of *Agnikarma* viz.:- *Valaya*, *Ardhchandra*, *Swastika*, etc. as per need by heated *Shalaka* in a smoke free fire of *Khadira* or *Badara* with the help a blower or a fan. During this period if patients feel discomfort then keep them satisfies by courageous, consolations talks, give cold water for drink and sprinkle cold water. But procedure of *Agnikarma* should be done till production of complete cauterisation.(6)

Post-Operative Measures –

Gritha and *madhu* should be applied over the wound for proper healing. Proper diet should be taken by patient after *Agnikarma* procedure

Contra-indications for Agnikarma:

- According to *sushrut*

Agnikarma should not be done in the *Pitta Prakriti*, *Bhinna Kostha*, *Durbalya*, *Vridhdha*, *Antah Shonita*, *Anuddhrata Shalya*, *Bala*, *Bhiru*, A person afflicted with a large number of *Vranas*, A person who is forbidden for *Swedana*. (7)

- According to *Charaka* *Agnikarma* should not be done in the *Vrana* of *Snayu*, *Marma*, *Netra*, *Kushtha* and *Vrana* with *Visha* and *Shalya*. (8)

- According to *Ashatgsangrha*, *Agnikarma* should not be done in the patient who takes *virechana*, suffering from *atisaar* (diarrhoea), who has *shalya* in his body, who has boils on body, who is contraindicated for *ksharkarma*. (9)

Superiority of Agnikarma:

Agnikarma is superior to *bheshaja*, *shastra* & *Ksharakarma* as a disease burnt with *Agni* will never reoccur. Disease which cannot be cured with medicines, *Kshara* and Surgery, can be cured with *Agni*. (10) There will be vaso-constriction due to heat and it will check the haemorrhage. (11)

CASE PRESENTATION: -

A 40-year-old left hand-dominant female, housewife with complaints of wrist pain at radial site for the past 4–6 weeks. She has no any history of trauma and no tingling or numbness. Pain is worse when she lifts up the children at home; hence, she is struggling to perform her household work.

She presents requesting treatment for this pain. The patient has taken counter anti-inflammatories intermittently, which have provided some relief. On physical examination, she had swelling and tenderness to palpation in the region of the first dorsal compartment (Fig.1), and her Finkelstein's test was positive. The remainder of her examination was unremarkable including symmetric range of motion of her wrists bilaterally. After she was diagnosed with de Quervain's tenosynovitis, the patient was given *Ruksha Agnikarma* in the following manner on 11-01-2020, 18-01- 2020 and 25-01-2020, suggested follow up after 15 days

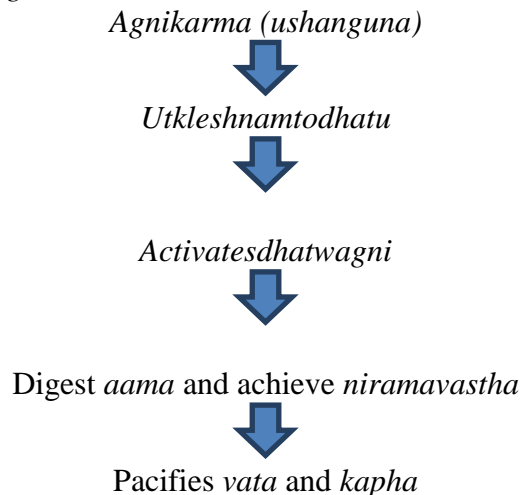
After the first sitting and second sitting of the *Agnikarma*, the Patient got relieved from the symptoms and after third sitting she got completely relieved from the symptoms, during follow up period also there were no complaints.

DISCUSSION: -

The De Quervain's tenosynovitis (*Manibandha Sandhi Sthita Snayugata Vata*) is produced by vitiated *Vata Dosha* with or without *Anubandha* of *Kapha*. So *Agnikarma* is considered the most preferred therapy to pacify these *Dosha*, by virtue of the properties that Agni possesses viz. *Ushna*, *Tikshna*, *Sukshma*, *Ashukari Guna*. These *Guna* are

opposite to the properties of *Vata* and *Kapha*.

Table 3: showing mode of action of *Agnikarma*



Its increases metabolism, blood circulation, decreases pain, stimulates nerves, relaxes muscles, decreases infection, decreases joint stiffness and inflammation.

CONCLUSION:

Agnikarma and its uses are described in *Ayurveda* much earlier than its utility was discovered by surgeons of rest medicine branches. However the technique and equipment's have become advanced and sophisticated, but the basic principles are still the same as that of Agni karma i.e use of energy- heat or current in the management of various diseases. Hence, this treatment modality can be prescribed as a clinical procedure considering its effectiveness and safe therapeutic regimen for De Quervain's tenosynovitis.

REFERENCES:

1. Hazani R, Engineer NJ, Cooney D, Wilhelmi BJ. Anatomic landmarks for the first dorsal compartment. *Eplasty*. 2008;8:e53. [[P MC free article](#)] [[PubMed](#)] [[Google Scholar](#)]
2. Lalonde DH, Kozin S. Tendon disorders of the hand. *Plast Reconstr Surg*. 2011;128(1):1e–14e. [[PubMed](#)] [[Google Scholar](#)]
3. Kay NR. De Quervain's disease. Changing pathology or changing perception? *J Hand Surg Br*. 2000;25(1):65–9. [[PubMed](#)] [[Google Scholar](#)]
4. Tripathi B. Carak Samhita, Vol. 2. Chikitsasthan 28 chapter Sloka No. 16: Varanasi: Chaukhamba Surabharati Publication; 2009. p. 937.
5. Dr.Anant Ram Sharma, edited with 'susrutavimarsini' Hindi commentary. (1st Ed.). *Susrutasamhita, maharshisusruta. sutrastan; Agnikarmavidhi -adhyaya: Chapter 12.verse no.10. Varanasi : Chukhambhaprakashan, 2010 ; page no.87.*
6. Dr.Subhashranade & G.R.Paranjape, edited with 'indutika' Marathi commentary. (1st Ed.). *Ashtang-snagraha, maharshivagbhat. sutra-stan; Agnikarmavidhi-adhyaya: Chapter 40.verse no.5.pune : Anmolprakashan, reprint 2006 ; page no.493.*
7. Dr.Anant Ram Sharma, edited with 'susrutavimarsini' Hindi commentary. (1st Ed.). *Susrutasamhita, maharshisusruta. sutrastan: Chapter 12.verse no.13. Varanasi : Chukhambhaprakashan, 2010 ; page no.87.*
8. Dr.Y.G. Joshi, Charak Samhita of maharshicharak, Chakrapanidatta, commentator Charakasamhita, 5th ed. Varanasi: Chaukhamba Sanskrit sansthana; 2001. Chikitsa sthana, 25/105; page no. 564.
9. Dr. Subhash Ranade & G.R.Paranjape, edited with 'indutika' Marathi commentary. (1st Ed.). *Ashtang-snagraha, maharshivagbhat. sutra-stan ;Agnikarmavidhi-adhyaya: Chapter 40.verse no.3.pune : Anmolprakashan, reprint 2006 ; page no.493.*
10. Dr.Anant Ram Sharma, edited with 'susrutavimarsini' Hindi commentary. (1st Ed.). *Susrutasamhita, maharshisusruta. sutrastan; Agnikarmavidhi-adhyaya: Chapter 12.verse no.3. Varanasi :*
11. Dr.Anant Ram Sharma, edited with 'susrutavimarsini' Hindi commentary. (1st Ed.). *Susrutasamhita, maharshisusruta. sutrastan; Agnikarmavidhi-adhyaya: Chapter 14.verse no.42. Varanasi: Chukhambhaprakashan, 2010 ; page no.112.*

Conflict of Interest: Non

Source of funding: Nil

Cite this article:

Role of Agnikarma in De Quervain's disease: a practical experience.

Kamalakar V. Gajare, Ketan P. Garje

Ayurlog: National Journal of Research in Ayurved Science- 2020; (8) (4):01-05